

WHY PUPPIES SHOULD NOT BE RACED TO YOUNG.

As most readers are aware, bodies are composed of millions of individual cells and their products. Specialised cells are grouped together to constitute tissues and various tissues combine to constitute organs. Organs are grouped into specialised systems and many such systems combine to make up a body, be it human or animal.

One of the tissues often overlooked is the so called "connective tissue" which holds all the more specialised tissues together, helping to make complex organs. Connective tissue is spread throughout the body, comprising of specialised living cells of its own as well as some of their tough inert products and at some sites it becomes quite well differentiated into recognisable component parts. Probably most notable among these are the tough fibrous sheets running between bundles of muscle cells then coalescing to form the tendons that by merging with the connective tissue support of the skeleton form firm attachments to the bones.

The bony skeleton may itself in fact be visualised as a particularly highly specialised part of the connective tissue system, the mineral deposits of bone being laid down by specialised cells suspended within the connective tissue net.

In young animals at birth, differentiation of all these connective tissue elements may not be very clear cut, and for example, X-rays may reveal bones to be only faint, ill-formed aggregations of mineral within a softish support system. Joints may be similarly ill defined and their limits which in adulthood are marked by strong well-defined sinews, membranous capsules and tendons may be difficult to make out with certainty even when the tissues are cut up and examined in detail.

Development from this phase of immaturity is, of course, rapid though less rapid than many dog owners appear to think. To allow for the enormous growth which has to occur in all bones, each lays down mineralised bone from several "ossification centres" which are separated by softish cartilaginous connective tissue interfaces.

These are eventually eliminated in mature bones as the bones from the several ossification centres coalesce, but until that occurs they constitute weak points and it is not uncommon for the ends of immature bones to shear off if unduly stressed at these points. Similarly if tendinous attachments to bones are unduly stressed there may be shearing at the nearest non-bony interface, or else detachment by traction of the important connective tissue sheath from around the developing bone, taking with it the vital layer of bone forming cells. At such sites bleeding and inflammatory reaction occurs with resultant lameness and sometimes disfiguring distortion of bone growth.

Another problem which relates to the system of bone growth by depositions of mineralised bone adjacent to non-bony interfaces occurs when one of these interfaces itself becomes involved in severe inflammatory reaction, as can occur following trauma, even as slight as a sharp blow while running. The usual consequence, is that the loose connective tissue is eliminated by premature deposition in it of mineral. This precludes the possibility of any further growth of bone at that interface. At best this may lead to a shortened or stunted bone, but if by chance only part of the interface is involved, it may lead to crippling and bizarre deformity as the inflamed interface closes and ceases to grow while its undamaged portion grows on leading to buckling of the bone. This deformity is seen most frequently involving the long bones above the wrist.

None of these problems can occur when growth of good quality bone is complete, and so it is obviously sensible to avoid imposition of undue stress on the bone until after this time. What is not generally regarded is the fact that in puppies growth of the long bones of the limbs cannot be regarded as complete before 14 months of age.

It is of course, not implied that puppies below this age should be denied exercise, but due regard to immaturity of bone and joint development should be paid before puppies are subjected to strenuous exercise. There is no doubt that

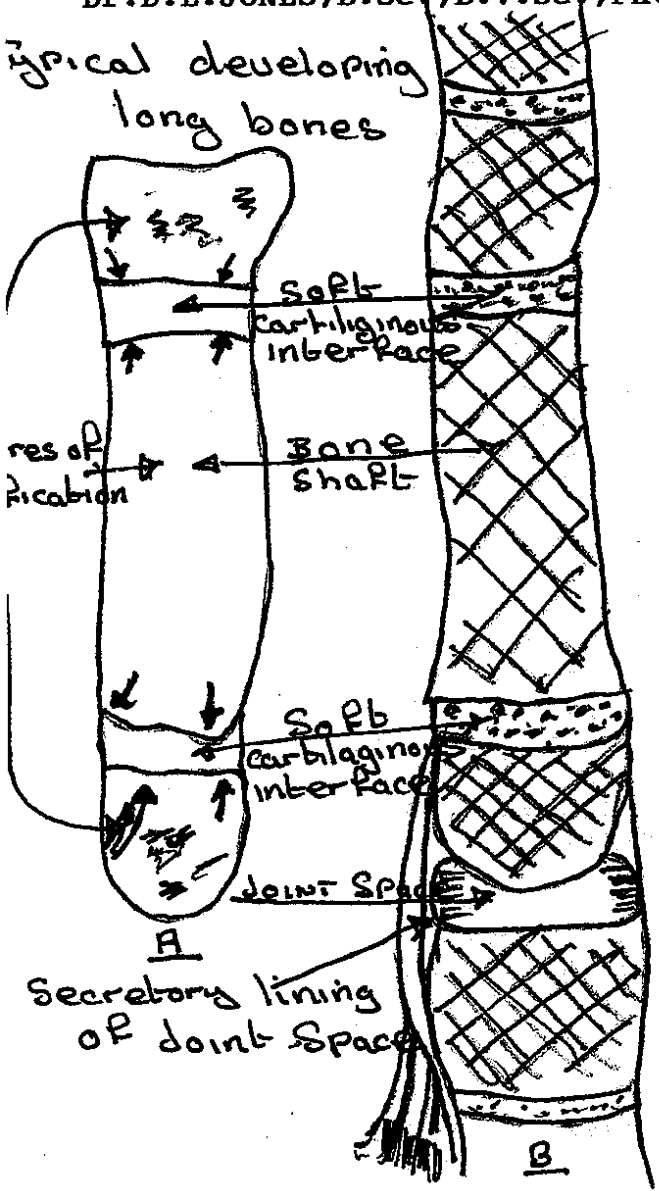
A

premature exposure to stress and excitement of racing exposes puppies to such a stress situation and it is small wonder that many promising animals are damaged by early damage of bone growth plates and joints. Regrettably, such damage is seldom permitted the opportunity of repair, for the very impatience that places an immature puppy into a risk situation is therefore incapable of permitting the very protracted rest period necessary for realistic repair to take place.

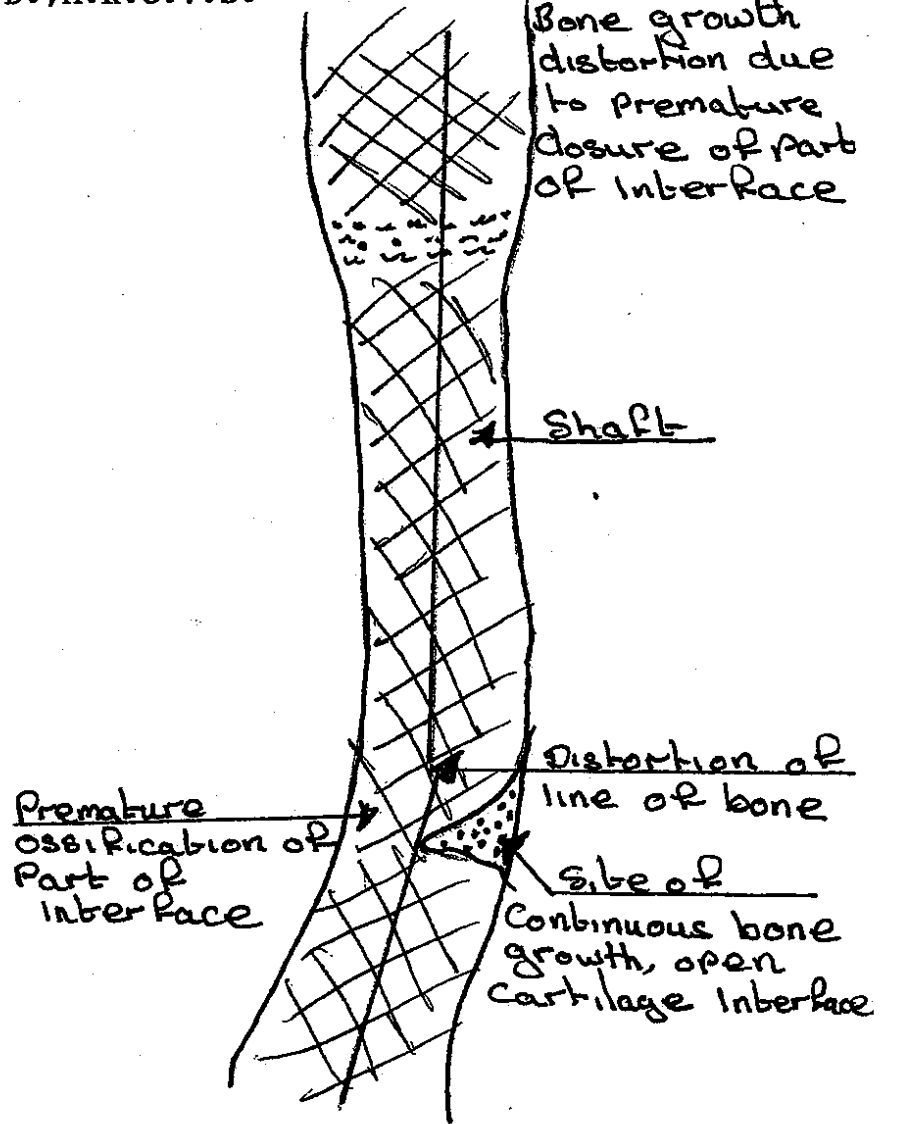
Ironically, ill-informed though well intentioned efforts to stimulate bone growth by supplementation of mineral and vitamin intake lead to an entirely separate bone growth problems, but these are commonly encountered in the giant breeds that are being "steamed up" in an effort to achieve early maturity for show ring success.....

Dr. D. E. JONES, B.Sc., B.V.Sc., Ph.D., M.R.C.V.S.

Typical developing long bones

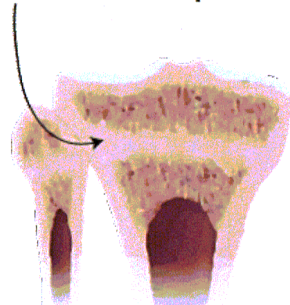


Bone growth distortion due to premature closure of part of interface



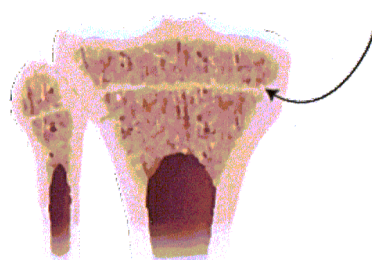
Immature bone seen in isolation
 Immature bone seen in association
 with surrounding tissue.

Growth Plate - open

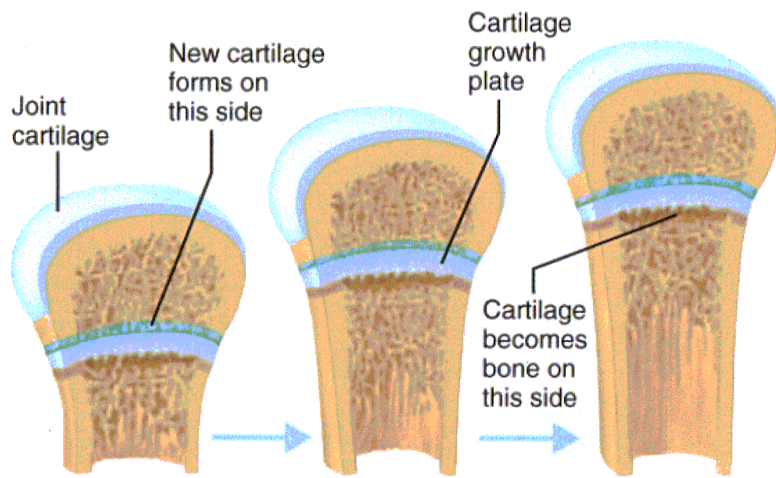


Puppy

Growth Plate - Closed
(Epiphyseal Line)



Adult



Copyright © 2001 Benjamin Cummings, an imprint of Addison Wesley Longman, Inc.